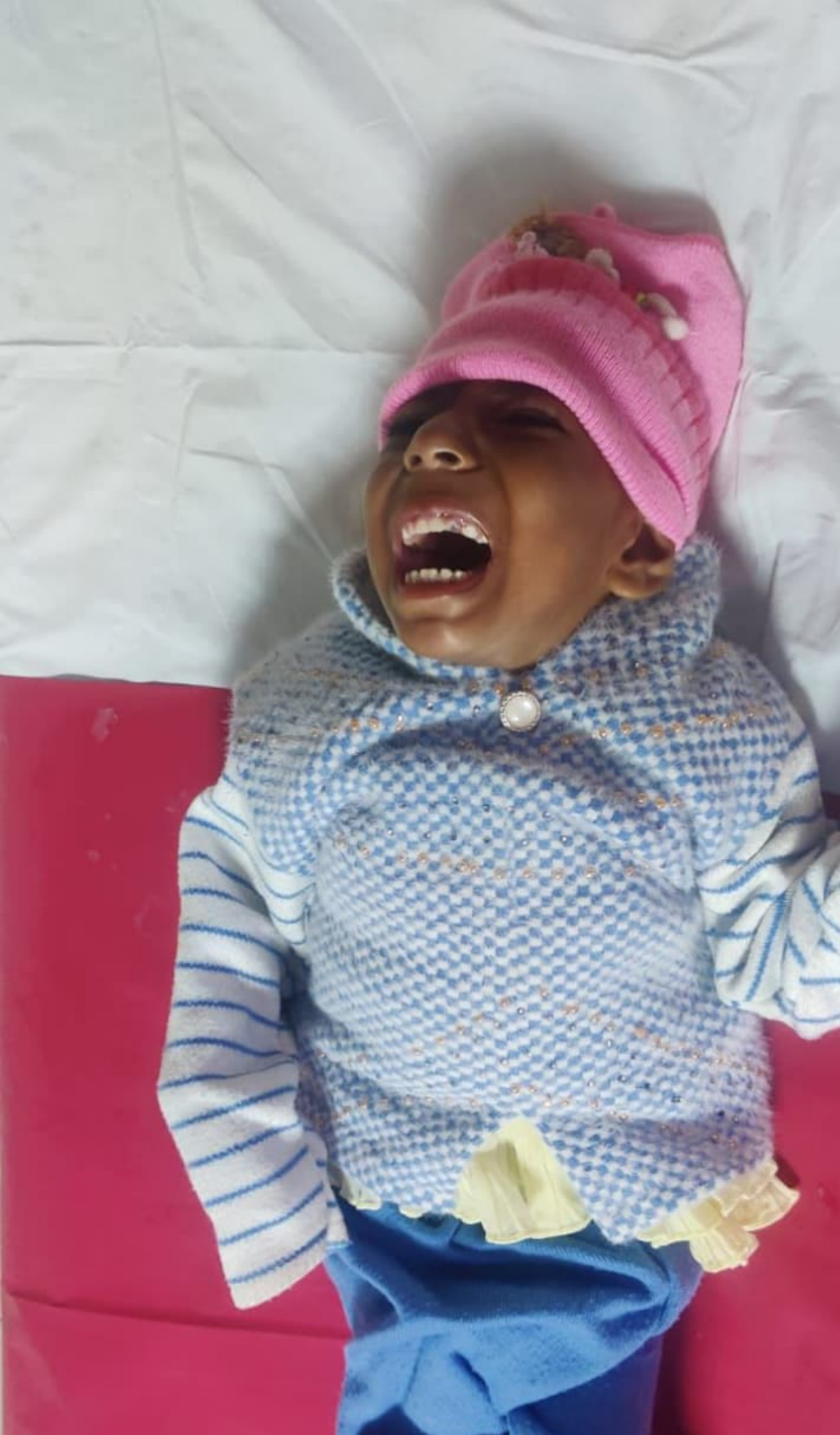

COVID ALERT! Wear

Area	Staff Name	Role	Status
01.01.21	...	...	...
01.02.21	...	...	...
01.03.21	...	...	...
01.04.21	...	...	...
01.05.21	...	...	...
01.06.21	...	...	...
01.07.21	...	...	...
01.08.21	...	...	...
01.09.21	...	...	...
01.10.21	...	...	...
01.11.21	...	...	...
01.12.21	...	...	...





19

ओ. पी. डी. पर्ची / OUT PATIENT TICKET

क.स.बा.अ.-13 (संगोषित)

KSCH-13 (Improved)

कलावती सरन बाल अस्पताल, नई दिल्ली

KALAWATI SARAN CHILDREN'S HOSPITAL, NEW DELHI

15/3/21

दिनांक / Date .....

ओ. पी. डी. प

नाम / Name

टीकाकरण विवरण

UHID: 20210055513      Fee: Rs. 0.00      TOKEN NO: 23  
 DATE: 17-09-2021 10:30:04 AM      General  
 MISS. AISHA  
 Age: 11M 19D (Female)      General OPD 6 PMR/II/120  
 D/O ASLAN  
 BULLAND SHAHR, Prayagraj, UTTAR PRADESH, INDIA  
 NON MLC Re-visit

दिनांक / Day

Tuesday

लिंग / Sex

लम्बाई / Height

हेपेटाइटिस-बी, ए  
Hep-B, OPV at

बी.सी.जी. BCG	NCCP Hep-B
डी.पी.टी., पोलियो, हेपेटाइटिस-बी DPT, Polio, Hep-B 1 <sup>st</sup>	done at hospital
डी.पी.टी., पोलियो, हेपेटाइटिस-बी DPT, Polio, Hep-B 2 <sup>nd</sup>	done at hospital
डी.पी.टी., पोलियो, हेपेटाइटिस-बी DPT, Polio, Hep-B 3 <sup>rd</sup>	done at hospital
खसरा एवं विटामिन ए Measles and Vitamin-A	done at home of girl
एमएमआर MMR	done at home of girl
डी.पी.टी. पोलियो (1 बोoster) DPT, Polio, (1 Booster)	done at home of girl
टाईफाइड वायरस Typhoid	done at home of girl
डी.पी.टी./ओ.पी.बी. (2 बस्टर) DPT, Polio, (2 Booster)	done at home of girl

90% No neck hoarsely  
 Increased tone all 4 limbs  
 NO social smile  
 Early intervention + stimulation  
 + acute improve they are to improve neck hoarsely sitting to support head eye coordination

दिनांक / Date .....

डॉक्टर के हस्ताक्षर / Signature of Doctor

128

ओ.पी.डी. पंजीकरण सं.

प्रारम्भिक निदान पर्चा

केवल अस्पताल के प्रयोग के लिए

O.P.D. Reg. No.

Provisional Diagnosis Slip

For Hospital Use Only

Issue: TBM - Hydrocephalus. @.

no e/o T ICF.

Surgery - 2 Episodes since d/s.

on Luvia @ 20.

? on Valproate @ 60

on clonazepam @ 0.5.

Steroids (Prednisolone) = for TBM.

GRD → 20 to } To continue ATT  
T Birth asphyxia. } from DOTS  
Sputa Quadriceps. } centre.

अपने बच्चे के अच्छे स्वास्थ्य के लिए आवश्यक जानकारी

1. बच्चे को सभी टीके समय पर लगवायें।  
\* 1 week.  
- Syp. Rifampicin (100mg/5ml).
  2. 6 माह तक मां अपना दूध ही पिलायें, तत्पश्चात् ऊपरी आहार के साथ साथ स्तनपान 2-3 वर्ष तक जारी रखें।  
- T. Isoniazid (100) 1/2 OD.
  3. जब शिशु 6 माह का हो जाये तब मां अपने दूध के अलावा घर में बने खाने में दाल, सूजी, दलिया, हरी सब्जियाँ, किला, रोटी, मक्खन, घी, चना, सत्तू आदि सब कुछ फेर बदल कर नियमित रूप से दें, 2-3 कटोरी दिन में 2-3 बार।  
- T. Pyrazinamide 500mg (1/2) OD.
  4. अतिसार (डायरिया) होने पर निम्नलिखित बातों का ध्यान रखें: बच्चे को मां का दूध पिलाते रहें, खिचड़ी, पतली दाल, सब्जियों का सूप, दही व केला दें। पानी उबालकर ठंडा करके उसमें ओआरएस पाउडर डालकर घोल बनाएं और बच्चे को बार-बार देते रहें। जिक की गोली या सिरन दस्त में लाभकारी हैं।  
- T. Ethambutol 400mg. 1/3 OD.
  5. खाजा बनाने व खाने से पहले हाथों को साबुन व साफ पानी से धोना जरूरी है।  
- T. Acetylsalicylic acid 100mg T  
- Syp. Luvia (1ml/100mg) 1 ml OD  
- Syp. Valproate (5ml/200mg)  
- T. clonazepam 5mg HS 2.5 ml OD
- TDS.
- T. Pantop 20mg 1/2 OD.

ओ. पी. डी. पर्ची / OUT PATIENT TICKET

क.स.ब.अ.-13 (संशोधन) /  
KSCH-13 (Improv)

**कलावती सरन बाल अस्पताल, नई दिल्ली**  
KALAWATI SARAN CHILDREN'S HOSPITAL, NEW DELHI

दिनांक / Date.....

यूनिट / Unit

दिन / Day

ओ. पी. डी. पंजी. सं. / O.P.D. Reg. No.

नाम / Na


लिंग / Sex

टीकाकरण

वजन / Weight

UHD:20210053513  
DATE:28-08-2021 09:21:12 AM  
MISS. AISHA  
Age: 11M (Female)  
D/O ASLAN  
BULLAND SHAHR, Prayagraj, UTTAR PRADESH, INDIA  
NON MLC

Fee: Rs. 0.00 TOKEN NO: 6  
General  
General OPD 11 Pediatric  
Medicine/III B/109



हेपेटाई  
Hep-

बी.सी  
BCC

डी.पी.टी., पालिया, हनपु  
DTP, Polio, Hep-B 1<sup>st</sup>

डी.पी.टी., पोलियो, हेपेटाईटिस-बी  
DTP, Polio, Hep-B 2<sup>nd</sup>

डी.पी.टी., पोलियो, हेपेटाईटिस-बी  
DTP, Polio, Hep-B 3<sup>rd</sup>

खसरा एवं विटामिन ए  
Measles Vitamin-A

एमएमआर  
MMR

डी.पी.टी. पोलियो (1 बूस्टर खुराक)  
DTP, Polio (1 Booster)

टाईफाइड का टीका  
Typhoid

डी.पी.टी./ ओ.पी.वी-(2 बूस्टर)  
DTP, Polio (2 Booster)

अन्य  
Others

Wt = 5 Kg.

D: 9-9-20

TBM in a k/c's GPPZ

Microcephaly.

ANC: uneventful.

Natal: S/T/NVD. DNCIAR. ? Mechanical

Ventilation x 7days/. D/S on  
oral medications (? AED). | 3 Kg  
↳ no documents available.

दिनांक / Date.....

डॉक्टर के हस्ताक्षर / Signature of Doctor

ओ.पी.डी. पंजीकरण सं.  
O.P.D. Reg. No.

प्रारम्भिक निदान पर्चा  
Provisional Diagnosis Slip

केवल अस्पताल के प्रयोग के लिए  
For Hospital Use Only



DEPTT.	ENT	HOSP. NO.	1004067	ROOM NO.	134 (DAILY)	OPD No.	15003						
NAME	BABY AYESHA	AGE	YEAR	MONTH	DAY	SEX	FEMALE	DATE TIME	25/11/202				
			2	2	10								
FATHER'S / MOTHER'S NAME	ASLAM	AREA / LOCATION	VILLAGE PARTA PUR BULANDSHAHAR BULAND SAHAR UTTAR PRADESH				DATE OF BIRTH						
BIRTH WT.(KG.)		WT. (KG.)	8.45		HEAD CIRCUMFERENCE(CMS)		HT. (CMS)	CONTACT NO.	972074115				
IMMUNIZATION	BCG	OPV		DPT			HIB			HEPATITIS B	MEASLES		
	1	2	3	B1	B2	1	2	3	B1	B2	1	2	3
PROVISIONAL DIAGNOSIS													
ICD 10 CODE													

INVESTIGATIONS  
CLINICAL PATHOLOGY

- V / TLC / DLC
- IC
- UR
- HAEMATELET COUNT
- WBC / CT / PT
- PERIPHERAL SMEAR
- URINE ROUTINE/MICROSCOPY
- BLOOD SUGAR
- BIOCHEMISTRY
- SUGAR F/PP/R
- UREA
- CREATININE
- URIC ACID
- ELECTROLYTES: NA/K
- CALCIUM
- PHOSPHORUS
- CHOLESTROL
- URINE (SPOT) CALCIUM/CREATININE RATIO
- URINE (SPOT) PROTEIN/CREATININE RATIO
- BILIRUBIN/T/D/I
- SGOT (ALT)
- SGPT (AST)
- ALK. PHOSPHATASE
- PROTEIN TOTAL
- ALBUMIN
- URINOLOGY
- RAY CHEST/OTHERS
- ECG
- US SCAN / MRI
- CPA SCAN
- USA SCAN
- CLINICAL MICROBIOLOGY
- URINE C/S
- LOOD C/S
- GP
- WIDAL
- DO
- ELISA/AG/HCV AB/HCV AB/HEV AB
- V
- HA PROFILE
- CUTUM FOR AFB
- ELISAS
- WIDOUX TEST

VITALS  
PULSE/HR \_\_\_\_\_/MIN  
RESPIRATORY RATE  
BREATHS/MIN  
TEMPERATURE \_\_\_\_\_ F

CLINICAL NOTES

Sp Impaired hearing

BERA Sp (Lt) side wave V at 70dB  
(Rt) wave at 50dB.

Advised for Hearing Aid trial & follow up  
Refer to Lok Nayak Hospital for further management (दिग्गज जी)

DR. NEHA JAIN  
Senior Professor  
Department of  
ENT, Chacha Nehru Bal Chikitsalaya  
Delhi-31

1.5T MRI

Multi Slice CT Scan

Digital X-Ray

Ultrasound


Colour Doppler

WS 7.8h

Kidney CP & Quadruplegia & Epilepsy (Uncontrolled)

22 OCT 2024  
21/19  
Nishu Bat Chhatrapati, D-31

Meningitis



Epilepsy -  $\frac{Control}{= pass}$

OI/PI  
↓  
S

Sip Levure (5/200)  
5ml — 5ml  
(5mg/5ml)

to 1mg/d, 5ml  
Sip Levure (1/100)

2.5 — 2.0  
(57mg/10ml)

Sip Levure 10ml HS  
K 3mg

3 tabs clonazepam (10)

7 Sip. Pramethine  
2.5ml tabs  
K 5mg

4 Sip zinnun (5/100)  
5ml tabs

8 Menth. 0.8h  
Sip D3

vit D3 (60,000) 1 PO stat



DEPT.	PEDIATRIC MEDICINE		HOSP. NO.	1004057	ROOM NO.	21 (TUE/FRI)		OPD No.	24031887
NAME	BABY AYESHA		AGE	YEAR: 5	MONTH: 19	DAY:	SEX: FEMALE	DATE TIME	04/10/2024 09
FATHER'S / MOTHER'S NAME	ASLAM		AREA / LOCATION	VILLAGE PARTA PUR BULANDSHAHR BULAND SAHAR UTTAR PRADESH			DATE OF BIRTH		
BIRTH WT.(KG.)	WT. (KG.)	8.4		HEAD CIRCUMFERENCE(CMS)	HT. (CMS)	CONTACT NO.		9720741157	
IMMUNIZATION	BCG	OPV		DPT			HIB	HEPATITIS B	MEASLES
	1	2	3	01	02	1	2	3	1
									Yes/No

LABORATORY INVESTIGATIONS: ICI/10 CODE

VITALS: PULSE/HR \_\_\_\_\_/MIN, RESPIRATORY RATE \_\_\_\_\_ BREATHS/MIN, TEMPERATURE \_\_\_\_\_ F

CLINICAL NOTES: TREATMENT ADVISED

K/C/O CP Diplegic T 53  


---

 - OTIPT - (50)  
~~P - 50 valproate (5/200) 5.5 mL B.D~~  
 5.5 mL - 5.5 mL  
~~50 Leverta (1/100) 2 mL p.o 12 hrs~~  
 2 mL - 2 mL  
~~50 Calcium (5/250)~~  
 2.5 mL OD.  
 X 1 Month  
~~50 Promethazine~~  
 2.5 mL 2.5 mL X 3 days  
 - Nasal clear drops  
 2 drops B/L nostril  
 6 hrs

Dr. R. P. S. Dhillon  
 Medical Officer



दिनांक

Date .....

- was started on MSF  $\rightarrow$  cow's milk.  
1:  $\frac{1}{2}$  dilution.
- was lethargic  $\oplus$ .
- no h/o seizure episode in the home.
- no tightening of limbs, <sup>after d/s -</sup> floppiness.
- h/o excessive irritability  $\oplus$ .
- h/o regurgitation of feeds  $\oplus$ .
- no h/o recurrent wheeze / FB / cough.
- h/o NB  $\oplus$  movements x 1 month.
- h/o Fever x 20 days.

h/o  $\oplus$   $\rightarrow$  multiple episodes in the form of tonic posturing of all 4 limbs, arching  $\bar{c}$  UREB lasting for 30 mins  $\rightarrow$ .  
? Post ictal drowsiness x 2 hrs.



## CHACHA NEHRU BAL CHIKITSALAYA

(An Autonomous institute Under Govt. Of NCT of Delhi,  
Affiliated to GGSIP University)



Name	Baby Ayesha	Age	1 Y	Ref. By	UNITII (PEDIATRIC MEDICINE)
UHID	0001004067	Sex	F	Sample Accepted at	30/03/2022 09:04
		Date	30/03/2022	Test Done at	30/03/2022 13:20

### Laboratory Report

Investigations	Observed Values	Unit	Biological Reference Range	Interpretation
<b>1. Liver Function Tests (LFT) (Specimen: BLOOD)</b>				
TOTAL BILIRUBIN	0.48			
DIRECT BILIRUBIN	0.19			
INDIRECT BILIRUBIN	0.29			
SGOT	22			
SGPT	12			
ALK. PHOSPHATASE	154			
TOTAL PROTEIN	6.66			
ALBUMIN	3.96			
GLOBULIN	2.70			
A/G RATIO	1.47			
GGT	16			
<b>2. Kidney Function Tests (KFT) (Specimen: BLOOD)</b>				
Urea	21			
Creatinine	0.33			
Uric Acid	2.7			
<b>3. S. crp (Specimen: BLOOD)</b>				
	2.9			
<b>4. S. Electrolytes (Specimen: BLOOD)</b>				
Sodium(Na)	137			
POTASSIUM(K)	4.39			
Chloride(Cl)	105			

Technician

Sujata

This is computer generated report no signature required.

Date &amp; Time of Print: 07/04/2022 11:00:43

S. Resident

Dr. Simarpreet Kukreja

Verified By

Dr. Shikha Sharma

Printed By: Shakuntla



wt 25kg  
4kg

NAME : BABY AYESHA Age/Sex : 3 Y/F  
UHID : 0001004067 Room No. : 413-4(B)  
DOA : 14/May/2024 DOD : 15/May/2024  
Mob No. : 9720741157 UNIT : UNITII (PEDIATRIC MEDICINE)

FINAL ICD DIAGNOSIS: Epilepsy. febrile triggered. bitemporal CP.

रोग निदान :

1 - Epilepsy

रोग इतिहास :

HISTORY: Fever - 1 day.  
Abnormal body movements - 1 day.  
Vomiting.

COURSE IN HOSPITAL:

child is a Hindu. Asphyxia / HIE / TBM / microcephaly.  
evolving CP (spastic quadriplegia). child on levetiracetam, Valproate  
child treated. loading of 1mg levetiracetam, valproate, ethosuximide, IV DNS and  
1mg ceftriaxone.

अन्वेषण :

INVESTIGATIONS CBC, CRP - (N)

INVESTIGATION	16/05/2024
CSF Culture	No Growth
CSF Cytology	-
PLC	ACTIVABLE
RBC	NO RBCS SEEN
REMARKS	KINDLY RULE OUT TRAUMATIC TAP
CSF-Pro	54
CSF-Sug	15

ANY SPECIAL PROCEDURE: -

ANY OPERATION OR PROCEDURE DONE: -

IMAGING STUDIES:

previous CT - cystic encephalomalacia involving  
B/L frontotemporo-parietal & occipital lobes. (21/12/2023)

किया गया उपचार :

TREATMENT RECEIVED

① 1mg Levetiracetam @ 50

② 1mg Valproate @ 60

③ IV fluids. (50% TFR)

CONDITION AT DISCHARGE:

Stable

ओ. पी. डी. पर्चा / OUT PATIENT TICKET

क.स.स.अ.-13 (सुधारीत)  
KSCH-13 (Improved)

**कलावती सरन बाल अस्पताल, नई दिल्ली**  
KALAWATI SARAN CHILDREN'S HOSPITAL, NEW DELHI

दिनांक / Date .....

यूनिट / Unit

दिन / Day

ओ. पी. डी. पंजी सं. / O.P.D. Reg. No.

नाम / Name

टीकाकार

हेपेटाइटिस  
Hep-B,

बी.सी.बी  
BCG

डी.पी.टी.

DPT, Polio, Hep-B 1<sup>st</sup>

डी.पी.टी., पोलियो, हेपेटाइटिस-बी  
DPT, Polio, Hep-B 2<sup>nd</sup>

डी.पी.टी., पोलियो, हेपेटाइटिस-बी  
DPT, Polio, Hep-B 3<sup>rd</sup>

खसरा एवं विटामिन ए  
Measles and Vitamin-A

एमएमआर  
MMR

डी.पी.टी. पोलियो ( 1 बूस्टर खुराक )  
DPT, Polio, (1 Booster)

टाइफाइड का टीका  
Typhoid

डी.पी.टी./ओ.पी.बी- ( 2 बूस्टर )  
DPT, Polio, (2 Booster)

अन्य  
Others

UHID:20210053513

Fee: Rs. 8.00 TOKEN NO: 8

DATE: 17-09-2021 10:30:29 AM General

MISS. AISHA

Age: 11M 1RD (Female)

Pediatric Ophthalmology T206

D/O ASLAN

BULLAND SHAHR, Prayagraj, UTTAR PRADESH, INDIA



NON MLC  
Re-visit

लिंग / Sex

लंबाई / Height

दिनांक / Date .....

डॉक्टर के हस्ताक्षर / Signature of Doctor

ओ.पी.डी. पंजीकरण सं.  
O.P.D. Reg. No.

प्रारम्भिक निदान पर्चा  
Provisional Diagnosis Slip

केवल अस्पताल के प्रयोग के लिए  
For Hospital Use Only



**CHACHA NEHRU BAL CHIKITSALAYA**  
(An Autonomous institute Under Govt. Of NCT of Delhi,  
Affiliated to GGSIP University)



Name	Baby Ayesha	Age	1 Y	Ref. By	UNITI (PEDIATRIC MEDICINE)
UHID	0001004067	Sex	F	Sample Accepted at	30/03/2022 09:04
		Date	30/03/2022	Test Done at	31/03/2022 10:26

**Laboratory Report**

Investigations	Observed Values	Unit	Biological Reference Range	Interpretation
<b>1. Complete Blood Counts / Complete Haemogram (Specimen: BLOOD)</b>				
RDW	20.5	%	8.0-15.5	
TLC	5.08	1000/cu.mm.	10-26	
RBC	5.00	10e6/mm cube	3.8-6.5	
<b>DLC</b>				
NEUTROPHIL	13.8			
LYMPHOCYTES	81.0			
MONOCYTES	3.5			
EOSINOPHILS	0.8			
BASOPHILS	0.9			
HGB	8.1	gm/dl	14-22	
HCT(PCV)	26.7	%	40-53	
MCV	53.3	fl	92-116	
MCH	16.3	pg	31-37	
MCHC	30.5	gm/dl	29-37	
PLT	354	10e3/mm cube	150-450	
<b>PERIPHERAL BLOOD SMEAR</b>				

Technician

Vandana

This is computer generated report no signature required.

Date &amp; Time of Print: 07/04/2022 11:00:53

S. Resident

Dr. Amir razi Khan

Verified By

Dr. Arti Khatri

Printed By: Shakuntla



Department of Empowerment of Persons with Disabilities,  
Ministry of Social Justice and Empowerment, Government of India

## Disability Certificate

Issuing Medical Authority, Bulandshahr, Uttar Pradesh



07/11/2022

Certificate No.: UP1110820200210166

This is to certify that I/we have carefully examined Kum. **Ayesha**, Daughter of Sri Ashish Kumar, Date of Birth **09/09/2020**, Age **2**, Female, Registration No. **0911/00000/2211/0193846**, resident of House No. **10**, Village **Partapur**, Post **Partapur**, **Bulandshahr - 245411**, Sub District **Bhawan Bahadur Nagar**, District **Bulandshahr**, State / UT **Uttar Pradesh**, whose photograph is affixed above, and I am/we are satisfied that:

(A) She is a case of **Mental illness**

(B) The diagnosis in her case is **Mental illness**

(C) She has **75%**(in figure) **Seventy Five** percent(in words) Permanent Disability in relation to her **Brain, BOTH EARS, Mental illness** as per the guidelines (Guidelines for the purpose of assessing the extent of specified disability in a person included under RPWD Act, 2016 notified by Government of India vide S.O. 76(E) dated 04/01/2019)

The applicant has submitted the following document(s) as proof of residence:

**Nature of Document(s):** Aadhaar card

312441

Signature / Thumb Impression of the Person with Disability

Signatory of notified Medical Authority Member(s)



Issuing Medical Authority, Bulandshahr, Uttar Pradesh

1.5T MRI

Multi Slice CT Scan

Digital X-Ray

Ultrasound

Colour Doppler

PATIENT'S NAME: BABY AYESHA

04 MONTH / F

REF. BY: SELF

DATE: 21.12.2020

NCCT HEAD


Contiguous 5mm spiral sections were taken from base of skull to vertex.

**Study reveals:**

- Areas of hypodensity noted in bilateral frontotemporoparietal and occipital lobes.
- Ex vacuo dilatation of bilateral lateral ventricle.
- Bilateral basal ganglia and thalami are normal.
- Third ventricle and midline structures are normal.
- Basal cisterns are normal.
- Cerebellum and brain stem are normal.
- The bony structures appear normal.

Impression: findings are suggestive of:

- Cystic encephalomalacia involving bilateral frontotemporoparietal and occipital lobes.
- Ex vacuo dilatation of bilateral lateral ventricle.

  
Dr. Sharad Jain  
DMRD, DNB (Radiodiagnosis)  
Consultant Radiologist

**SRIVASTAVA**  
**MRI & IMAGING CENTRE**

E-mail : srivastavamri@gmail.com | srivastavamrijasola@gmail.com  
Website : www.srivastavamriandimagingcentre.com

Date	07/04/2022	Srl No.	1	Sex	F
Name	BABY AYESHA	Age	1 Yrs. 6 Mn.		
Ref. By	Dr. DHEERAJ GUPTA	Ref. Hosp			

**MRI BRAIN**

MR Imaging of the brain was performed in axial, coronal and sagittal planes using high resolution dedicated head coil in T1, T2, Fast Flair weighted sequences.

The study reveals evidence of cystic encephalomalacia with gliosis in bilateral frontal, temporal parietal and occipital lobes with loss of volume and dilated lateral and third ventricles. The third ventricle is of normal calibre. No midline shift.

Myelination pattern of the brain is normal. Gray white matter differentiation is normal.

Brainstem, bilateral basal ganglia and thalami are normal in signal characteristics. The hypothalamus is unremarkable.

Basal cisterns, fissures and sulcal spaces are unremarkable. The pituitary gland is normal in size, shape, outline and signal characteristics. The sellar, suprasellar and retrosellar CSF spaces are unremarkable.

Cerebellar hemispheres are normal in signal characteristics. The C.P. angles are normal. 7<sup>th</sup>, 8<sup>th</sup> nerve complexes are unremarkable. The vascular structures reveal normal flow voids.

**OPINION:-** MR features reveal cystic encephalomalacia with gliotic changes and dilated lateral ventricles likely representing hypoxic ischaemic insult sequelae involving bilateral frontal, temporal, occipito-parietal lobes.

Please correlate clinically.

Dr. SANJAY SRIVASTAVA  
M.B.B.S , D.M.R.D, D.N.B.

Sr. CONSULTANT RADIOLOGIST

This is only a professional opinion and should be correlated in the light of clinical findings. Not for Medical Legal Purposes

1,2,3 & 6, PURVANCHAL PLAZA, POCKET B LSC MARKET, MAYUR VIHAR, PHASE II, DELHI - 110091 (T) 011-22779009, 43051331 (M) 9811892896

UNIT NO. 20,21,22 & 25 SPLENDOR FORUM, G.F. JASOLA DISTRICT CENTRE, Near Apollo Metro Station, Gate No. 1, DELHI-25 (T) 011-41090077, 011-41080077, (M) 70116

SRIVASTAVA CLINIC FOR WOMEN AND FOR ULTRASOUND, M1, SECTOR 11, MAIN ROAD, NOIDA 201301 (T) 0120-4329993 (M) 9811892896

(A unit of Srivastava Diagnostic Centre)





CHACHA NEHRU BAL CHIKITSALAYA  
(AN AUTONOMOUS INSTITUTE UNDER  
GOVT. OF NCT OF DELHI,  
AFFILIATED TO GGSIP UNIVERSITY)  
GEETA COLONY, DELHI 110031



<b>NAME</b>	: BABY AYESHA	<b>AGE/SEX</b>	: 3 Y/F
<b>UHID</b>	: 0001004067	<b>Room No.</b>	: 44-1(B)
<b>DOA</b>	: 03/Nov/2023	<b>DOD</b>	: 03/Nov/2023
		<b>UNIT</b>	: UNIT III (PEDIATRIC MEDICINE)

**FINAL ICD DIAGNOSIS: SPECIAL EPILEPTIC SYNDROMES**

**DIAGNOSIS: K/C/O TBM (TREATED) WITH SEIZURE D/O**

**REASON FOR ADMISSION: ABNORMAL MOVEMENT**

**ANY UNTOWARD EVENT DURING HOSPITAL STAY:**  
No

**INVESTIGATION REPORT:**

**ADVICE OF DISCHARGE:**

SYP LEVERA (1/100) 2ML Po Bd  
SYP VALPROATE 5ML Po Bd  
SYP CALCIUM 5ML Po Od

60

**NAME AND SIGNATURE OF ADMITTING CONSULTANT / SR**



### RNTCP TB Identity Card, Bulandshahar

Name AYSHA D/DASLAM

Sex  M  F  TG Age: 1 year

Address: Postapur

Contact No: \_\_\_\_\_

Aadhar ID \_\_\_\_\_

PHI: BBNAGAR

TU: BBNAGAR

#### Site of Disease

Pulmonary  Extra pulmonary

#### Type of Patient

- New
- Recurrent
- Treatment after Lost to Follow up
- Treatment after Failure
- Other Previously treated
- Transferred in

#### Case Definition

- Microbiologically
- Clinically diagnosed

#### Treatment regimen:

- Confirmed New
- Previously treated

#### Appointment Dates

9/9/2021	25/9/2021	8/10/2021
22/10/2021		
8/11/2021	13/11/2021	11/01/2022
5/2/22	19/2/22	5/3/22
19/3/22	2/4/22	30/4/22
28/5/22	25/6/22	



बाबा नेहरू बाल चिकित्सालय,  
(राष्ट्रीय राजधानी क्षेत्र, दिल्ली सरकार)  
मौला अज़दीकी, दिल्ली-110031  
**CHACHA NEHRU BAL CHIKITSALAYA**  
(AFFILIATED TO MAULANA AZAD MEDICAL COLLEGE)  
(GOVT. OF NCT OF DELHI)  
GEETA COLONY, DELHI-110093  
आगतक बास / VISITOR'S PASS



अंग सं/ S.No. 1004067

दिनांक/Date 03.11.2023

रोगी का नाम  
Name of the Patient Aysha

वार्ड का नाम  
Name of Ward Bm

सीड आर सं  
C. R. No. 15522

नवीकरण यदि कराया है तो  
Renewal if any for. \_\_\_\_\_

विरार सं  
Bed No. \_\_\_\_\_

[Signature]

उत्तर अधिकारी

नोट: यह पास जारी होने के तुरंत से वैध है। इसे तीन दिनों के लिए प्रयोग करें।  
Note: This Pass is valid for three days from the date of issue.



बाबा नेहरू बाल चिकित्सालय,  
(राष्ट्रीय राजधानी क्षेत्र, दिल्ली सरकार)  
मौला अज़दीकी, दिल्ली-110031  
**CHACHA NEHRU BAL CHIKITSALAYA**  
(AFFILIATED TO MAULANA AZAD MEDICAL COLLEGE)  
(GOVT. OF NCT OF DELHI)  
GEETA COLONY, DELHI-110093  
आगतक बास / VISITOR'S PASS



अंग सं/ S.No. 21

दिनांक/Date 11/31/24

रोगी का नाम  
Name of the Patient Aysha

वार्ड का नाम  
Name of Ward Bm

सीड आर सं  
C. R. No. 2040

नवीकरण यदि कराया है तो  
Renewal if any for. \_\_\_\_\_

विरार सं  
Bed No. \_\_\_\_\_

[Signature]

नोट: यह पास जारी होने के तुरंत से वैध है। इसे तीन दिनों के लिए प्रयोग करें।  
Note: This Pass is valid for three days from the date of issue.

DEPT	WING (PEDIATRIC MEDICINE)	WOSP. NO.	WOSP. NO.	ROOM NO.	21 (TUE/FRI)	CPD NO.	1000000000
NAME	BABY AYESHA	AGE	1	11	59	SEX	FEMALE
PROVISIONAL DIAGNOSIS							
SYMPTOM							

DEPT	WING (PEDIATRIC MEDICINE)	WOSP. NO.	WOSP. NO.	ROOM NO.	21 (TUE/FRI)	CPD NO.	1000000000	
NAME	BABY AYESHA	AGE	1	11	59	SEX	FEMALE	
FATHER'S / MOTHER'S NAME	ASLAN	AREA / LOCATION	VILLAGE PATA PUR BILANDIPUR BILAND SAHAR LITTA PRADESH			DATE OF BIRTH		
BIRTH WT (KG.)	WT. (KG.)	7.7kg		HEAD CIRCUMFERENCE (CM)	HT. (CM)	CONTACT NO.	WFO (P/1)	
IMMUNIZATION	BCG	OPV	1	2	3	1	2	
PROVISIONAL DIAGNOSIS								

INVESTIGATIONS  
 CLINICAL PATHOLOGY  
 HB / TLC / DLC  
 AEC  
 PLATELET COUNT  
 BT / CT / PT  
 PERIPHERAL SMEAR  
 URINE ROUTINE/MICROSCOPY  
 ALBUMIN/SUGAR  
 BLOOD CHEMISTRY  
 TL, SUGAR, TP/PPK  
 BL, UREA  
 S. CREATININE  
 S. URIC ACID  
 S. CALCIUM  
 S. PHOSPHORUS  
 CHOLESTROL  
 URINE (SPOT) CALCIUM/CREATININE RATIO  
 URINE (SPOT) PROTEIN/CREATININE RATIO  
 S. BILIRUBIN/T/D/T  
 SGOT (ALT)  
 SGPT (AST)  
 S. ALP PHOSPHATASE  
 S. PROTEIN TOTAL  
 S. ALBUMIN  
 RADIOLOGY  
 X-RAY CHEST/OTHERS  
 USG  
 CT SCAN / MRI  
 DTPA SCAN  
 DMSA SCAN  
 CLINICAL MICROBIOLOGY  
 URINE C/S  
 BLOOD C/S  
 CRP  
 S. WIDAL  
 ASO  
 HBS/AG/HCV AB/HCV AN/HEV AB  
 HIV  
 ANA PROFILE  
 SPUTUM FOR AFB  
 OTHERS  
 HANTOX TEST

for TBM  
E microlpny

for M/s

OT/OT (50)

Syvalpme  
 5c - 5c

Sypleveq  
 1m - 1m

Tab clabaz

(Sy) HSON

Sy mulhe  
 2.5c - 2.5c

OL

Aer  
 + onos/09/22

Sy pny 4 veses

Sy pny 2.5c/22 x

CHBC - 140

DR. TAJ GUPTA  
 D.C.M.  
 Chief Medical Officer  
 Chacha Nemo  
 An Authorized Medicine Shop  
 BABA CLINIC, BABA 110031

Microcephaly  
 now ~ 90% abnormal body movement  
 fever x 4 days.

abnormal body movement in form of twitching of  
 & LL also frequently & unprovoked of eye ball,  
 each episode last for 3-4 min, abate over its  
 fever. documented x10 of, 3-4 episode in a day.  
 continuous, relieved by medication.

wt = 7 kg

& His: On Levea @ 35 mg/kg/day  
 valproate @ 30 mg/kg/day  
 clonazepam @ 0.7 mg/kg/day

Temp = 97.7 F  
 of E: alert

MI - 144be < 3 sec  
 H - 82/min  
 SpO2 - 99%

Adm:  
 30ml NS @ 20mg/kg/day

Dx - 105

HC = 38.5 cm

CSF, Tons T/T  
 P/T

Plan:

MRE Brain  
 EEG  
 Pan 3/5 / 3/5 1 week  
 3/5 3/5

Reflex: K B B  
 P B B  
 P ↑ ↑

- Syplenera (200mg/1ml) 0.8 ml po @ 45mg/kg/day
- Sypl Valproate (200mg/5ml) 2.5 ml po @ 30mg/kg/day
- Tab clonazepam 5mg po
- Sypl Calcium (250mg) 5ml po
- Sypl MVI 5ml po
- CDC Referral
- Fluor pads OPD - Mon/Thurs @ 9am

Prerna  
 (SR)



NAME	: BABY AYESHA	AGE/SEX	: 2 Y/F
UHID	: 0001004067	ROOM No.	: 44-2(C)
DOA	: 17/MAY/2023	DOD	: 17/MAY/2023
		UNIT	: UNETH (PEDIATRIC MEDICINE)

FINAL ICD DIAGNOSIS: EPILEPSY

DIAGNOSIS: Epilepsy

REASON FOR ADMISSION: Seizure

ANY UNTOWARD EVENT DURING HOSPITAL STAY:

Valproate loading given uneventfully.

INVESTIGATION REPORT:

ADVICE OF DISCHARGE: ~~Syp. Valproate 5ml - 5ml.~~

Syp Leves 1ml - 1ml.  
 Syp lalchix 3ml o.d

.....IN CASE OF EMERGENCY CONTACT AT 011-21210215,16 (EXTN. 230) OR VISIT CNBC EMERGENCY DEPARTMENT.

Syp IFA 3ml o.d

NAME AND SIGNATURE OF ADMITTING CONSULTANT / SR

Fluoride / Fri Jan.

